



PATIENT

Gucci Franceschi

PRESENTING CLINICAL SIGNS

History: Grade 2/6 heart murmur. Assess prior to anesthesia. CXR: NSF.
BP: 121, 114mmHg

SPECIES

Canine

ELECTROCARDIOGRAPHIC FINDINGS

A six lead ECG is available at 50mm/s; 10mm/mV. The average heart rate is 150bpm (range 136-176bpm). The rhythm is sinus in origin, with a p for every QRS complex and vice versa. The P wave morphology is positive with a normal dimension. Normal PR. The QRS morphology is positive with normal dimension. MEA is normal. No ectopic beats, pauses or dysrhythmias observed.

BREED

Pitbull

ECG diagnosis: Normal sinus rhythm with respiratory variation.

SEX

Female

ECHOCARDIOGRAM FINDINGS

2D, m-mode, color flow and doppler imaging is available. Minimal diffuse thickening of mitral valve leaflets with no obvious prolapse into the left atrial lumen. No mitral regurgitation is identified. Normal left atrial dimension. Normal LV diameter with adequate myocardial function. The tricuspid valve appears subjectively normal, with no tricuspid regurgitation. The right heart is normal (subjective). No overt evidence of pulmonary arterial hypertension. The pulmonic and aortic valves are normal in morphology and mobility. No aortic abnormalities identified, however the LVOT velocity is mildly elevated. Normal pulmonic outflow velocities. No aortic or pulmonic insufficiency. No pericardial or pleural effusion noted. No cardiac tumors observed.

AGE

14 months

WEIGHT

68.6lbs

CARDIAC CHART

INTERPRETED BY

Maggie Machen Lamy,
DVM, DACVIM
(Cardiology)

CANINE CARDIAC PARAMETERS	MR VMAX (m/s)	TR VMAX (m/s)	LA/AO (Boon method)	LA/AO (Heart Base; Swe)	FS (%)	EF (%)	EPSS (cm)
NORMAL PARAMETER	4.5-5.5	<2.7	1.3	<1.6	28-40	40-100	<0.6
PATIENT	NA	NA	NM	1.4	37	68	0.28
CANINE CARDIAC PARAMETERS	HR (BPM)	AV VMAX (m/s)	PV MAX (m/s)	BODY WEIGHT (kg)	LA 2D short axis Base view (cm)	LVIDd Avg; 2D and m-mode short axis (cm)	LVIDs Avg; 2D and m-mode short axis (cm)
NORMAL PARAMETER	50-100	0.7-1.7	0.7-1.6	BELOW	BELOW	BELOW	BELOW
PATIENT	NM	2.5	1.7	31.1	3.0	4.0	2.5
*Normal chamber parameters expressed as a mean value (SD)				3	1.27 (5.3)	2.46 (2.46)	1.36 (5.5)
BODY WEIGHT DEPENDENT PARAMETERS				5	1.40 (4.5)	2.74 (5.2)	1.60 (4.7)
<i>*Note: All measurements based upon multi-modal images and methods. An average value is reported.</i>				10	1.50 (3.8)	3.27 (3.5)	2.06 (3.1)
				15	1.83 (2.0)	3.71 (2.4)	2.43 (2.1)
				20	2.02 (1.9)	4.14 (2.2)	2.80 (2.0)
				25	2.18 (2.4)	4.48 (2.9)	3.10 (2.5)
				30	2.33 (3.3)	4.83 (3.9)	3.39 (3.4)
				35	2.48 (4.3)	5.17 (5.0)	3.69 (4.5)
				40	2.62 (5.2)	5.48 (6.1)	3.96 (5.4)
				50	2.88 (7.1)	6.07 (8.3)	4.46 (7.4)

Adapted from June Boon, Veterinary Echocardiography, 1998
Rishniw M and Hollis NE, J Vet Intern Med 2000; 14:429-435
Hansson et al, Vet Rad and Ultrasound 2002
Bonagura et al. Echocardiography: principles of interpretation, Vet Clin North Am 15:1177, 1995

IMAGING PERFORMED BY

Loetitia St-Jacques,
LVT/RVT

HOSPITAL NAME

Alpine Animal Hospital

REFERRING VET

Dr. Sjoin

INVOICE

24346

DATE

5/23/22



PATIENT

Gucci Franceschi

SPECIES

Canine

BREED

Pitbull

SEX

Female

AGE

14 months

WEIGHT

68.6lbs

INTERPRETED BY

Maggie Machen Lamy,
DVM, DACVIM
(Cardiology)

IMAGING PERFORMED BY

Loetitia St-Jacques,
LVT/RVT

HOSPITAL NAME

Alpine Animal
Hospital

REFERRING VET

Dr. Sjoin

INVOICE

24346

DATE

5/23/22

INTERPRETATION OF THE FINDINGS & FURTHER RECOMMENDATIONS

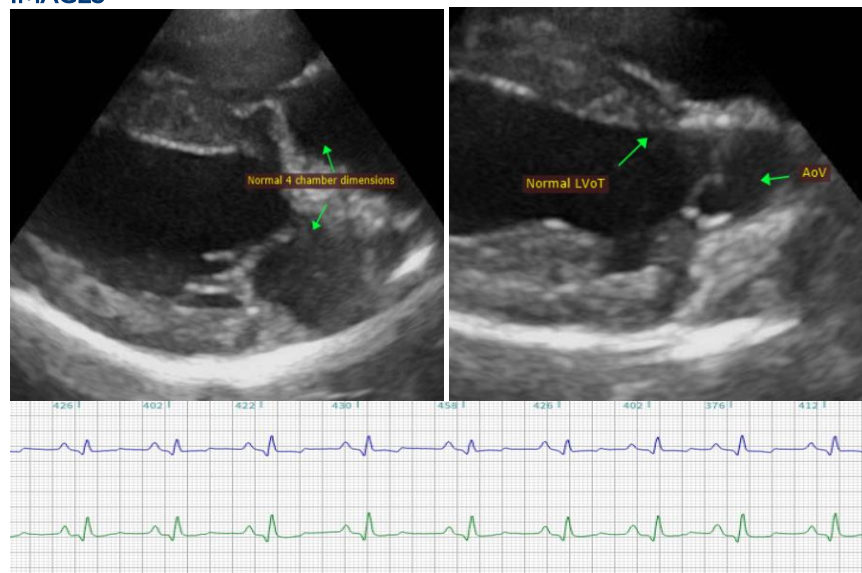
The only cause of a murmur identified is increased flow velocity through the LVOT/aortic root. No obvious subaortic ridge or valvular abnormalities are visualized, and in the absence of structural abnormalities this is considered a benign flow murmur. If this is a new murmur, it is reasonable to monitor periodically via recheck echocardiography in the future. Additionally screening for fluid status abnormalities (dehydration, anemia, etc.) is recommended through routine lab work as these abnormalities would make this finding more prevalent. No significant valvular insufficiencies were noted, and no structural issues identified. The ECG is unremarkable with a normal sinus rhythm.

No cardiac medications are indicated. No cardiac contraindication for general anesthesia.

Monitor for any development of cough, labored breathing or exercise intolerance.

Recommend recheck echocardiogram in 12-18 months to screen for progression or development of concurrent cardiac disease that the preexisting murmur may mask.

IMAGES



The information and recommendations provided are based on the images presented by the referring veterinarian. No evaluation can be communicated regarding pathology that was not visible in the image/video clips provided.

Thank you for this referral. This report was generated using transcription software, and minor dictation errors may be present. If the clinical or image interpretation does not parallel your findings or if I can be of any further assistance, please contact me.

Maggie Machen Lamy, DVM
Diplomate of the American College of Veterinary Internal Medicine (Cardiology)
info@sonopath.com



Portable Animal Western Sonography, Inc.

IMAGING PERFORMED BY
pawsonography@gmail.com  530-786-8340

PATIENT

Gucci Franceschi

SPECIES

Canine

BREED

Pitbull

SEX

Female

AGE

14 months

WEIGHT

68.6lbs

INTERPRETED BY

Maggie Machen Lamy,
DVM, DACVIM
(Cardiology)

**IMAGING
PERFORMED BY**

Loetitia St-Jacques,
LVT/RVT

HOSPITAL NAME

Alpine Animal
Hospital

REFERRING VET

Dr. Sjloin

INVOICE

24346

DATE

5/23/22